

ソラフェニブ（商品名；ネクサバル）は、外科的切除不能、又は局所療法が適用されない肝細胞癌患者さんなどに広く用いられている経口マルチキナーゼ阻害薬ですが、“分子標的”薬でありながら、実際には治療前にどの患者さんに効果があり、どの患者さんに効果がないという効果予測を立てることができませんでした。我々は今回、c-kitの発現が確認された珍しい原発性肝癌に対し、治療効果が得られるであろうと考えソラフェニブを投与し高い治療効果が得られた症例、つまり治療前に効果があることの予測に成功した世界初の貴重な症例を経験したので報告しました。ソラフェニブの効く人には様々な要因があると考えられますが、そのうちのひとつの指標を見つけたと考えています。この報告は偶然ではなく、我々が今まで幹細胞マーカー陽性肝癌にこだわり研究してきたからこそ生まれた成果と考えています。今後も継続してどのような患者さんにどのような薬の効果があるのか（癌の個性）をふまえ、一つ一つ基礎研究、臨床経験を積んでいきエビデンスを新潟から発信していけるよう努めたいと考えます。

（清野智、土屋淳紀 筆）

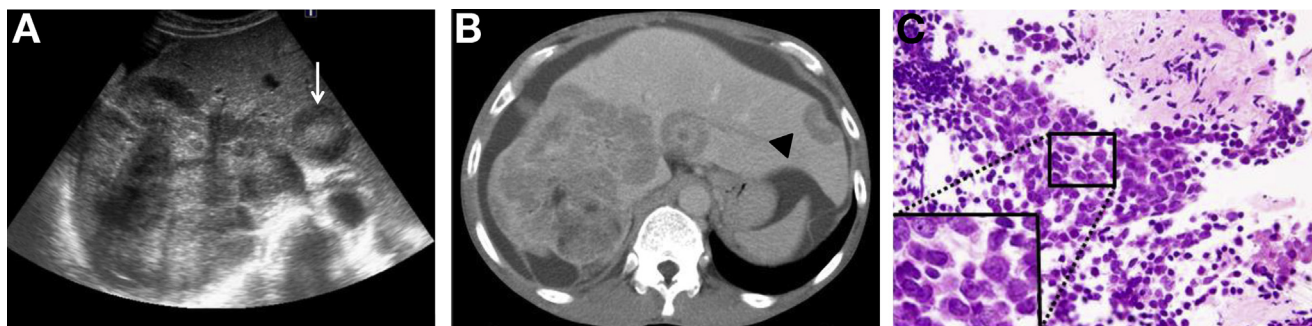A Rare Primary Liver Tumor That Responded to Sorafenib



Satoshi Seino,^{1,2} Atsunori Tsuchiya,² and Masashi Watanabe¹

¹Department of Gastroenterology and Hepatology, Niigata Prefectural Shibata Hospital, Shibata City, and

²Department of Gastroenterology and Hepatology, Graduate School of Medical and Dental Science, Niigata University, Niigata City, Niigata, Japan



Question: A 63-year-old man with prior hepatitis B infection was transferred to our hospital with a chief complaint of pretibial edema and abdominal distention. Although he drank 500 mL of beer daily, he had no history of serious disease and was not taking any medications. On admission, the patient was afebrile and his abdomen was soft but slightly distended. He also had pretibial edema. Laboratory data on admission revealed normal white blood cell count, hemoglobin level, and platelet count. His liver panel revealed total bilirubin of 1.9 mg/dL (normal, 0.2–1.2 IU/L), aspartate aminotransferase of 47 IU/L (normal range, 13–33 IU/L), alanine aminotransferase of 29 IU/L (normal range, 8–42 IU/L), alkaline phosphatase of 957 IU/L (normal range, 115–359 IU/L), and γ -glutamyl transpeptidase of 437 IU/L (normal range, 10–47 IU/L). The levels of α -fetoprotein, carcinoembryonic antigen, and carbohydrate antigen 19-9 were all within the normal range, as was the proportion of fucosylated α -fetoprotein.

Abdominal ultrasonography and contrast-enhanced computed tomography (CT) were then performed, revealing a huge tumor occupying the majority of the right lobe of the liver, and some smaller tumors in the left lobe. The center of the tumors was high echoic, and the periphery of the tumors was low echoic (resembling the bull's eye sign of metastatic liver tumor) on ultrasonography (Figure A; white arrow). The tumors were not hypervascular, and the contrast dye was not washed out rapidly from the tumors in the late phase of enhanced CT (Figure B). Some tumors at the surface of the liver formed umbilication, which is also often seen in metastatic liver tumors (Figure B; black arrowhead). Gastroduodenoscopy, colonoscopy, and whole body CT were performed to distinguish between primary and metastatic liver tumors; however, no primary lesion was detected except for that in the liver. To assess the primary lesion further, tumor biopsy was performed from a nodule (Figure A; white arrow). Hematoxylin and eosin staining revealed small round-shaped cells with high nuclear/cytoplasmic ratio surrounded by fibrous tissue (Figure C).

What is the most likely diagnosis, and what marker was employed for immunohistochemistry to assess the utility of treatment with sorafenib?

Look on page 1227 for the answer and see the *Gastroenterology* web site (www.gastrojournal.org) for more information on submitting your favorite image to Clinical Challenges and Images in GI.

Acknowledgments

The authors thank Kazuyoshi Takizawa, Kiyotaka Tsuboi, Hiromitsu Oka, Yo-hei Aoki, Kazuhide Yamazaki, Jun Matsuzawa, Masaaki Natsui (Department of Gastroenterology and Hepatology, Niigata Prefectural Shibata Hospital), Yasuo Seino (Department of Radiology, Niigata Prefectural Shibata Hospital), Kunihiko Wakaki (Department of Pathology, Niigata Prefectural Shibata Hospital) and Minoru Nomoto (Department of Gastroenterology and Hepatology, Graduate School of Medical and Dental Science, Niigata University) for their cooperation.

Conflicts of interest

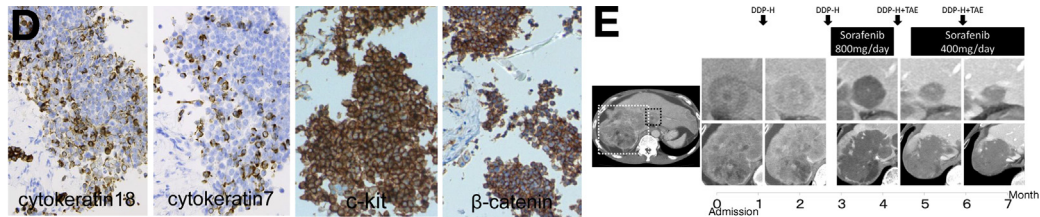
The authors disclose no conflicts.

© 2014 by the AGA Institute

0016-5085/\$36.00

<http://dx.doi.org/10.1053/j.gastro.2014.07.035>

Answer to the Clinical Challenges and Images in GI Question: Image 3 (page 1226): c-kit-Positive Liver Cancer (Hepatic Progenitor Cell Marker-Positive Tumor)



Immunohistochemistry of liver biopsy tissue revealed that the tumor included cholangiocytic lineage marker cytokeratin (CK)7-positive cells and hepatocytic lineage marker CK18-positive cells (Figure D). Small numbers of periodic acid–Schiff staining, Heppar1, and NCAM-positive cells were also detected. Of particular importance, the round-shaped small cells were all positive for β -catenin and hepatic progenitor cell (HPC) marker c-kit (Figure D). Based on these data, we diagnosed these tumors as most likely combined hepatocellular–cholangiocarcinoma with stem cell features, intermediate cell subtype, according to the 2010 World Health Organization Classification. Arteriportal shunt was detected in the huge tumors in the right lobe; therefore, 100 mg of DDP-H (CDDP powder; IA-call) was administrated intra-arterially. However, a therapeutic effect was not obtained. Sorafenib (800 mg/d) was employed as a second-line therapy owing to the high positivity of c-kit, which is one of its targets. As we expected, the tumor responded and gradually decreased in size. During the sorafenib treatment, arteriportal shunt in the tumor disappeared; therefore, transarterial embolization was added regularly (Figure E). The patient remains well approximately 1 year after the first diagnosis.

C-kit is one of the HPC markers, and 2.3% of hepatocellular carcinomas are c-kit positive. However, the positivity of c-kit has not yet been accurately analyzed.¹ Sorafenib is a multikinase inhibitor that is widely employed for the management of unresectable hepatocellular carcinoma; however, it is not employed for specific targets in liver cancer. To the best of our knowledge, this is the first report concerning the treatment efficacy of sorafenib for highly c-kit–positive liver cancer. Although it is well known both that c-kit is one of the targets of sorafenib and that subanalysis of the SHARP study suggested that the soluble c-kit high group had a greater response to sorafenib than the soluble c-kit low group, no immunohistochemical evidence of c-kit expression in the tumor has been reported.² Zhang et al³ used sorafenib for c-kit positive renal cell carcinoma and had better responses and obtained longer overall survival time compared with those for c-kit–negative renal cell carcinoma. Although c-kit–positive liver cancers are rare, they may respond to sorafenib; therefore, liver biopsy should be considered for these atypical liver tumors.

References

1. Becker G, Schmitt-Graeff A, Ertelt V, et al. CD117 (c-kit) expression in human hepatocellular carcinoma. *Clin Oncol (R Coll Radiol)* 2007;19:204–208.
2. Llovet JM, Pena CE, Lathia CD, et al. Plasma biomarkers as predictors of outcome in patients with advanced hepatocellular carcinoma. *Clin Cancer Res* 2012;18:2290–2300.
3. Zhang HL, Zhu Y, Qin XJ, et al. c-KIT: potential predictive factor for the efficacy of sorafenib in metastatic renal cell carcinoma with sarcomatoid feature. *Clin Genitourin Cancer* 2013;11:134–140.

For submission instructions, please see the *Gastroenterology* web site (www.gastrojournal.org).